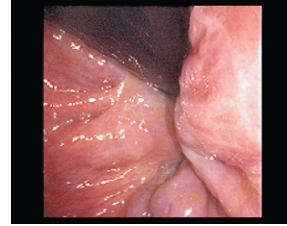
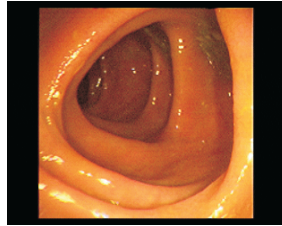
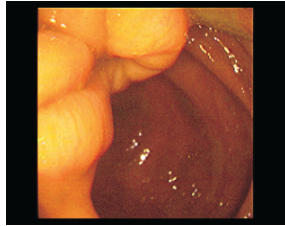
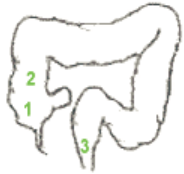

Sample Endoscopy Center  
1000 Main Street  
Suite 101  
Anytown, NY 10011

Pt Name: John Doe

DOB: 12/11/1976  
Referral: David Alcid, MD  
SS #: 26786548  
Chart #: 132468  
Date: 12/16/2002

## COLONOSCOPY REPORT



1:Cecum: Appendiceal orifice

2:Ascending colon: Normal

3:Anus: Internal hemorrhoids

### Indications:

The patient is being seen for rectal bleeding and abdominal pain.

### Procedure:

Colonoscopy was performed with the following results:

### Findings:

**Rectum:** Internal hemorrhoids

**Sigmoid:** Within normal limits.

**Descending:** Within normal limits.

**Transverse:** A 3 cm, pedunculated polyp was removed with snare electrocautery.

**Ascending:** Within normal limits.

**Cecum:** Within normal limits.

### Impressions:

1. Colon polyp
2. Internal hemorrhoids

### Recommendations:

1. Await pathology
2. Primary care follow-up
3. Repeat colonoscopy in one year
4. Anusol HC suppositories qHS times 7 days